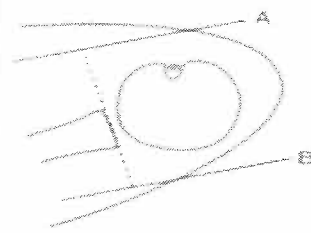








Radiology of Huntsville MRI Protocol 1-3.0Tesla Shoulder-Routine

Sequence #	Coil:		Shoulder-Phased Array Coil	
	1	2	3	4
Sequence Type:	PDFS	T2 FSE/Fat-Sat	T1	T2 FSE/Fat-Sat
Orientation:	Axial	Coronal	Sagittal	Sagittal
Field of View (cm):	15	15	15	15
Slice Thickness	4	3.5	3	3
Gap	0.8	0.8	0.8	0.8
Contrast	No	No	No	No
Matrix:	256 x 256	256 x 224	256 x 256	256 x 192
Nex:	3 Nex	4 Nex	2 Nex	6 Nex


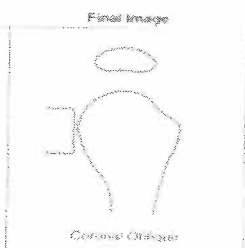
<p>Scout</p> 	<ul style="list-style-type: none"> • Axial scout • Obtain coronal oblique images perpendicular to glenoid articular surface (dashed line) • Cover from line A to B • Film from posterior to anterior • Obtain coronal plane first (most valuable) 	<p>Final Image</p>  <p>Coronal Oblique</p>
<p>Scout</p> 	<ul style="list-style-type: none"> • Coronal scout • Obtain axial images • Cover from line C at acromion to line D at inferior glenoid 	<p>Final Image</p>  <p>Axial</p>
<p>Scout</p> 	<ul style="list-style-type: none"> • Axial scout • Obtain sagittal images parallel to glenoid articular surface • Cover from line E at glenohumeral joint to line F at edge of humeral head 	<p>Final Image</p>  <p>Sagittal Oblique</p>

Radiology of Huntsville MRI Protocol 1-3.0 Tesla Shoulder-Post Arthrogram

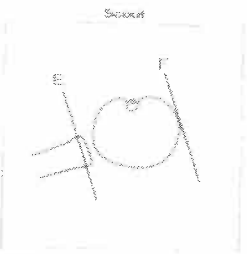
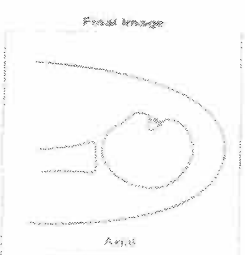
Sequence #:	Coil:		Shoulder/Phased Array			
	1	2	3	4	5	6
Sequence Type:	T1	T2FS	T1FS	T1	T1FS	T1FS
Orientation:	Axial	Coronal	Coronal	Sagittal	Sagittal	ABER
Field of View (cm):	15	15	15	15	15	15
Slice Thickness(mm):	4	3.5	3.5	2.5	2.5	4
Gap:	0	0.8	0.8	0.5	0.5	0
Contrast:	Post Arthrogram					
Matrix:	256 x 256	256 x 224	256 x 256	256 x 256	256 x 192	256 x 192
Nex:	2 Nex	2 Nex	2 Nex	3 Nex	3 Nex	2 Nex



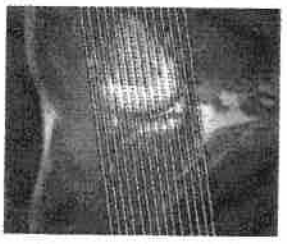
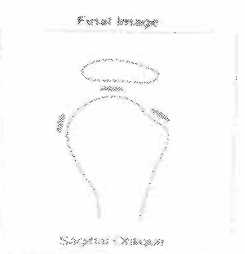- Axial scout
- Obtain coronal oblique images perpendicular to glenoid articular surface (dashed line)
- Cover from line A to B
- First from posterior to anterior
- Obtain coronal plane first (most available)



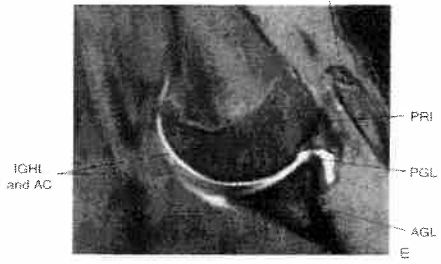- Coronal scout
- Obtain axial images
- Cover from line C at acromion to line D at inferior glenoid



- Axial scout
- Obtain sagittal images parallel to glenoid articular surface
- Cover from line E at glenohumeral joint to line F at edge of humeral head

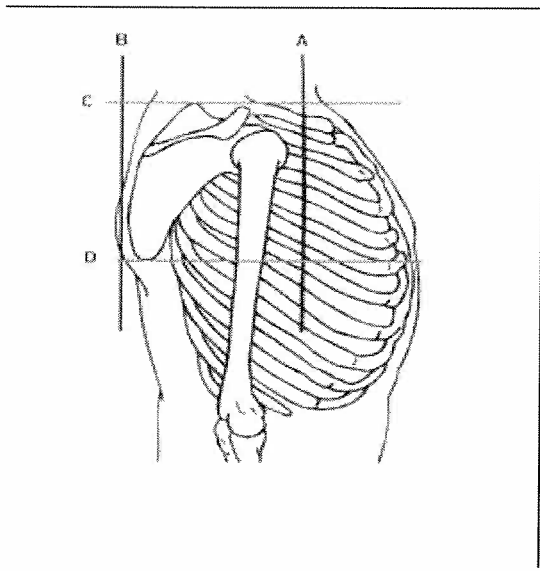


Direct coronal localizer for oblique axial abducted and externally rotated (ABER) images. Oblique axial sections are aligned with the long axis of the humerus on a coronal localizer acquired with the patient in the ABER position.

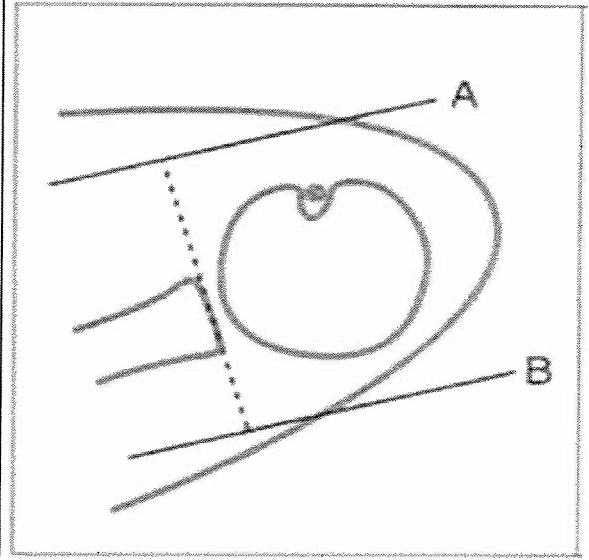


Radiology of Huntsville MRI Protocol: Scapula

Sequence #:	Coil:		Array Body Coil			
	1	2	3	4	5	6
Sequence Type:	T1 FSE	T2*	T2 FSE	STIR	T2 FSE	T1
Orientation:	Coronal	Axial	Sagittal	Sagittal	Axial	Axial
Field of View (cm):	16	14	14	14	14	16
Slice Thickness(mm):	4	4	4	4	4	4
Gap:	0	0	1	1	0	0
Contrast:	No	No	No	No	No	No
Matrix:	256 x 224	256 x 224	256 x 224	256 x 224	256 x 224	256 x 224
Nex:	3 Nex	2 Nex	3 Nex	3 Nex	2 Nex	2 Nex



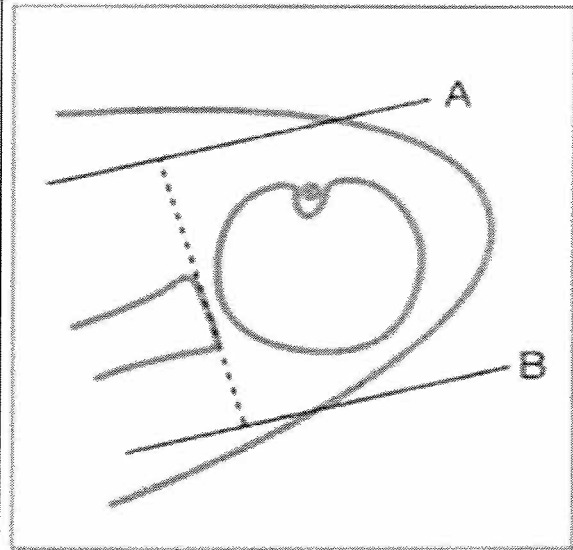
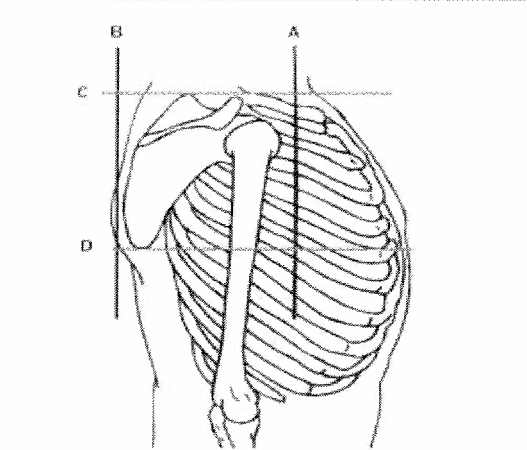
Scout



Radiology of Huntsville MRI Protocol: Scapula Mass/Pathology

Sequence #:	Coil:		Array Body Coil		Scapula Mass/Pathology	
	1	2	3	4	5	6
Sequence Type:	T1	STIR	MSFS	T1FS	T1FS Post Gd	T1FS Post Gd
Orientation:	Axial	Sagittal	Coronal	Coronal	Axial	Coronal
Field of View (cm):	14	14	16	16	14	16
Slice Thickness(mm):	4	4	4	4	4	4
Gap:	1.5	1.5	1.5	1.5	1.5	1.5
Contrast:	No	No	No	No	Yes	Yes
Matrix:	256 x 224	256 x 224	256 x 224	256 x 224	256 x 224	256 x 224
Nex:	3 Nex	3 Nex	2 Nex	3 Nex	3 Nex	2 Nex







Scout

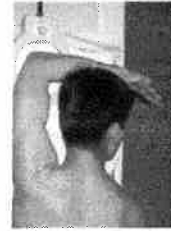

Radiology of Huntsville MRI Protocol:					Elbow - Routine	
Sequence #:	Coil:				***IF BICEPS INJURY***	
Sequence #:	1	2	3	4	5	6
Sequence Type:	T2-FSE/Fat-Sat	T2-FSE/Fat-Sat	T1 SE	T2-FSE/FatSat	T2-FSE/Fat-Sat	T1 SE
Orientation:	Coronal	Sagittal	Axial	Axial	FABS	FABS
Field of View (cm):	15	15	14	14	15	15
Slice Thickness(mm):	3	3	4	4	4	4
Gap:	0.5	1	0.5	0.5	0.5	0.5
Contrast:	No	No	No	No	No	No
Matrix:	256 x 256	256 x 256	256 x 256	256 x 256	256 x 256	256 x 256
Nex:	4	1	2	3	3	2

*If Poor Fat Sat on Coronal - Perform STIR)

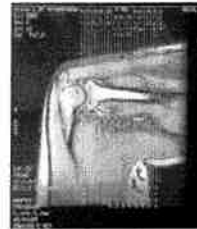Elbow MRI

Scout		Final Image
	<ul style="list-style-type: none"> Coronal scout Obtain axial images parallel to line B, tangent to humeral olecranon surface Cover from line A (distal humeral metaphysis) to C (proximal radial metaphysis) Axials should be obtained in first flexion extension plane Final image should be entire frame 	 <p>Axial</p>
	<ul style="list-style-type: none"> Axial scout Obtain coronal images parallel to line connecting proximal olecranon anteriorly Cover from line D to E Coronals should be obtained in second plane 	 <p>Coronal</p>
	<ul style="list-style-type: none"> Axial scout Obtain sagittal images perpendicular to coronal plane Cover from line F to G First and last images should include epicondyles too Sagittals should be obtained as first plane (best rotation) 	 <p>Sagittal</p>



View larger version:
 • In this page • In a new window
 • Download as PowerPoint Slide

Figure 2. Photograph illustrates the FABS position. (Reprinted, with permission, from reference 4.)



View larger version:
 • In this page • In a new window
 • Download as PowerPoint Slide

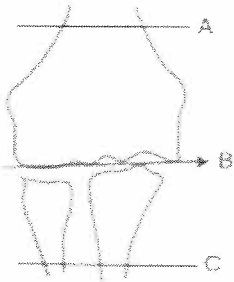
Figure 3. Localization image shows a FABS view with planned sections oriented perpendicular to the radial shaft. (Reprinted, with permission, from reference 4.)

Radiology of Huntsville MRI Protocol Elbow-Post Arthrogram

Sequence #:	Coil:		Knee Coil vs Flex Wrap		5
	1	2	3	4	
Sequence Type:	T1 SE	T2 Fat Sat	T1 Fat Sat	T2FS	T2FS
Orientation:	Axial	Axial	Coronal	Coronal	Sagittal
Field of View (cm):	14	14	14	14	14
Thickness/Gap	4/0.5	4/0.5	3/0.5	3/0.5	3mm/1
Contrast:	Post Arthrogram				
Matrix:	256x256	256x256	256x256	256x256	256 x 256
Nex:	2	3	2	6	1


Elbow MRI

Scout




- Coronal scout
- Obtain axial images parallel to line B, tangent to humeral condyle surface
- Cover from line A (distal humeral metaphysis) to C (proximal radial metaphysis)
- Axials should be obtained as first (most valuable) plane
- Final image should fill entire frame

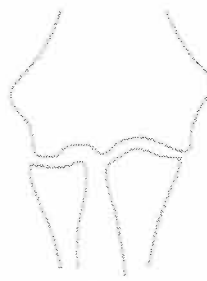Final Image



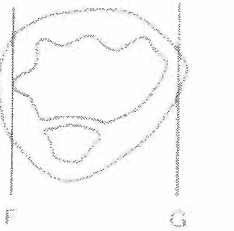
Axial



- Axial scout
- Obtain coronal images parallel to line connecting humeral condyles anteriorly
- Cover from line D to E
- Coronals should be obtained as second plane



Coronal



- Axial scout
- Obtain sagittal images perpendicular to coronal plane
- Cover from line F to G
- First and last images should include epicondyle tip
- Sagittals should be obtained as last plane (most valuable)

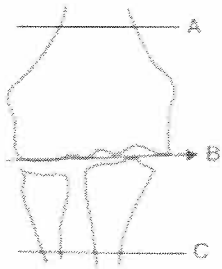

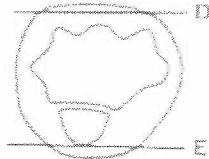





Sagittal

Radiology of Huntsville MRI Protocol: Elbow - Infection / Mass



Sequence #:	1	2	3	4	5	6	7
Sequence Type:	T1 SE	T1 SE FatSat	STIR	STIR	T1 TSE	T1 FS Post Gd	T1 FS Post Gd
Orientation:	Axial	Coronal	Axial	Coronal	Sagittal	Axial	Coronal
Field of View (cm):	12	12	12	12	12	12	12
Slice Thickness(mm):	4	4	4	4	4	4	4
Gap:	1	1	1	1	0.5	1	1
Contrast:	No	No	No	No	No	Yes	Yes
Matrix:	192x256	192x256	192x256	192x256	192x256	192x256	192x256
Nex:	2	3	2	3	2	2	3

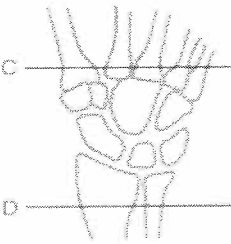

Elbow MRI

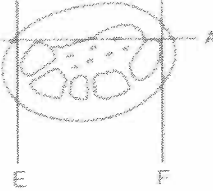

Scout		Final Image
	<ul style="list-style-type: none"> • Coronal scout • Obtain axial images parallel to line B, tangent to humeral condyle surface • Cover from line A (distal humeral metaphysis) to C (proximal radial metaphysis) • Axials should be obtained as first (most valuable) plane • Final image should fill entire frame 	 <p align="center">Axial</p>
	<ul style="list-style-type: none"> • Axial scout • Obtain coronal images parallel to line connecting humeral condyles anteriorly • Cover from line D to E • Coronals should be obtained as second plane 	 <p align="center">Coronal</p>
	<ul style="list-style-type: none"> • Axial scout • Obtain sagittal images perpendicular to coronal plane • Cover from line F to G • First and last images should include epicondyle tips • Sagittals should be obtained as last plane (least valuable) 	 <p align="center">Sagittal</p>

Radiology of Huntsville MRI Protocol: Wrist

	1	2	3	4	5
Sequence #:	1	2	3	4	5
Sequence Type:	PDFS	PDFS	T1	T2FS	T2-Gradient
Orientation:	Axial	Sagittal	Coronal	Coronal	Coronal
Field of View (cm):	12	12	12	12	12
Slice Thickness(mm):	3	3	3	3	2
Gap:	0.2	0.5	0	0	0
Contrast:	No	No	No	No	No
Matrix:	256 x 256	256 x 200	256 x 256	256 x 200	320 x 256
Nex:	2	2	3	2	3

Scout		Final Image
	<ul style="list-style-type: none"> • Axial scout • Obtain coronal images tangent to line A • Cover from line A to B • Coronals should be first sequence in study (most valuable plane) • Final image should include bases of metacarpals and distal radioulnar joint 	

Scout		Final Image
	<ul style="list-style-type: none"> • Coronal scout • Obtain axial images between lines C and D • Final image should fill the entire frame 	


Scout		Final Image
	<ul style="list-style-type: none"> • Axial scout • Obtain sagittal images perpendicular to line A • Cover from line E to F • Sagittal should be last sequence in study (least valuable plane) 	

- Patient prone with wrist in coil above head, elbow in flexion
- Coil centered on point 1 cm distal to palpated ulnar styloid
- Conduct, padding, relax fingers, toe crosses

Radiology of Huntsville MRI Protocol: Trauma Screening


	Coil:	
Sequence #:	1	2
Sequence Type:	T1	STIR
Orientation:	Coronal	Coronal
Field of View (cm):	14	14
Slice Thickness(mm):	4	4
Gap:	0	0
Contrast:	No	No
Matrix:	192 X 256	192 X 256
Nex:	3	2

Scout



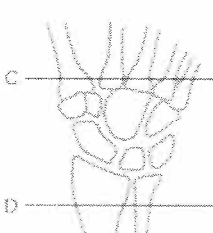
- Axial scout
- Obtain coronal images targeted to line A
- Cover from line A to B
- Coronal should be first sequence in study (most valuable plane)
- Final image should include bases of metacarpals and distal radioulnar joint

Final Image




Coronal

Scout



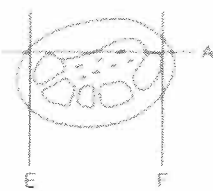
- Coronal scout
- Obtain axial images between lines C and D
- Final image should fill the entire frame

Final Image




Axial

Scout



- Axial scout
- Obtain sagittal images perpendicular to line A
- Cover from line E to F
- Sagittal should be last sequence in study (least valuable plane)

Final Image




Sagittal

- Patient prone with wrist in coil above head, allow in flexion
- Coil centered on point 1 cm distal to palpated ulnar styloid
- Comfort, padding, relaxed fingers, air circled

Radiology of Huntsville MRI Protocol: Wrist-Infection/Mass

Sequence #:	Coil:					
	1	2	3	4	5	6
Sequence Type:	T1	T1FS	STIR	STIR	T1FS-PostGd	T1FS-PostGd
Orientation:	Coronal	Axial	Coronal	Sagittal	Coronal	Axial
Field of View (cm):	14	14	14	14	14	14
Slice Thickness(mm):	4	3	4	3	4	3
Gap:	0	0.2	0	0.2	0	0.2
Contrast:	No	No	No	No	Yes	Yes
Matrix:	224 x 256	192 X 256	192 X 256	192 X 256	224 x 256	192 X 256
Nex:	2	3	2	3	2	3


Scout



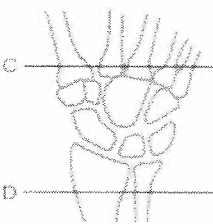
- Axial scout
- Obtain coronal images longest to line A
- Cover from line A to B
- Coronals should be first sequence in study (most valuable plane)
- Final image should include bases of metacarpals and distal radioulnar joint

Final Image

Coronal




Scout



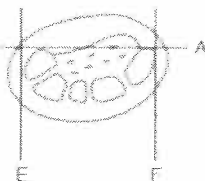
- Coronal scout
- Obtain axial images between lines C and D
- Final image should fit the entire frame

Final Image

Axial




Scout



- Axial scout
- Obtain sagittal images perpendicular to line A
- Cover from line E to F
- Sagittal should be last sequence in study (least valuable plane)

Final Image



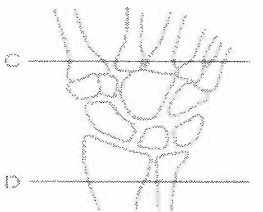



Sagittal



- Patient prone with wrist in coil above head, elbow in flexion
- Coil centered on point 1 cm distal to palpated ulnar styloid
- Comfort, padding, relaxed fingers are crucial

Radiology of Huntsville MRI Protocol: Wrist-Post Arthrogram

Sequence #:	Coil:		Knee Coil vs Flex Wrap/Wrist Coil		
	1	2	3	4	5
Sequence Type:	PDFS	T1 Fat Sat	T2 FS (or STIR)	T2 - Gradient	T1
Orientation:	Axial	Coronal	Coronal	Coronal	Sagittal
Field of View (cm):	10	12	12	12	12
Slice Thickness(mm):	3	3	3	2	3
Gap:	0.2	0	0	0	0.5
Contrast:	Post Arthrogram				
Matrix:	256 x 256	256 x 200	256 x 200	320 x 256	256 x 200
Nex:	2	2	2	3	2



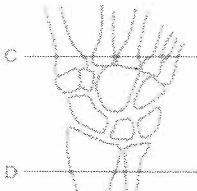

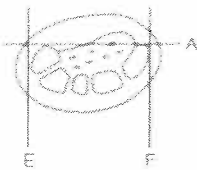

<p align="center">Scout</p> 	<ul style="list-style-type: none"> • Axial scout • Obtain coronal images tangent to line A • Cover from line A to B • Coronals should be first sequence in study (most valuable plane) • Final image should include bases of metacarpals and distal radius/ulna joint 	<p align="center">Final Image</p> <p align="center">Coronal</p> 
<p align="center">Scout</p> 	<ul style="list-style-type: none"> • Coronal scout • Obtain axial images between lines C and D • Final image should fill the entire hand 	<p align="center">Final Image</p> <p align="center">Axial</p> 
<p align="center">Scout</p> 	<ul style="list-style-type: none"> • Axial scout • Obtain sagittal images perpendicular to line A • Cover from line E to F • Sagittal should be last sequence in study (most valuable plane) 	<p align="center">Final Image</p> <p align="center">Sagittal</p> 

- Patient prone with wrist in and above hand, elbow in flexion
- Cast centered on hand 1 cm distal to proximal ulnar styloid
- Comfort, padding, relaxed fingers and thumb

Radiology of Huntsville MRI Protocol:

Hand

Sequence #:	Coil:					
	1	2	3	4	5	6
Sequence Type:	T2FS	T2FS or STIR	T1	PD Fat-Sat	PDFS	SPGR
Orientation:	Axial	Coronal	Sagittal	Coronal	Axial	Coronal
Field of View (cm):	14	14	14	14	14	16
Slice Thickness(mm):	3	4	4	4	3	1.2
Gap:	0.2	0	0.2	0	0.2	0
Contrast:	No	No	No	No	No	No
Matrix:	192 X 256	192 X 256	192 X 256	192 X 256	192 X 256	256 x 256
Nex:	4	2	3	3	4	2

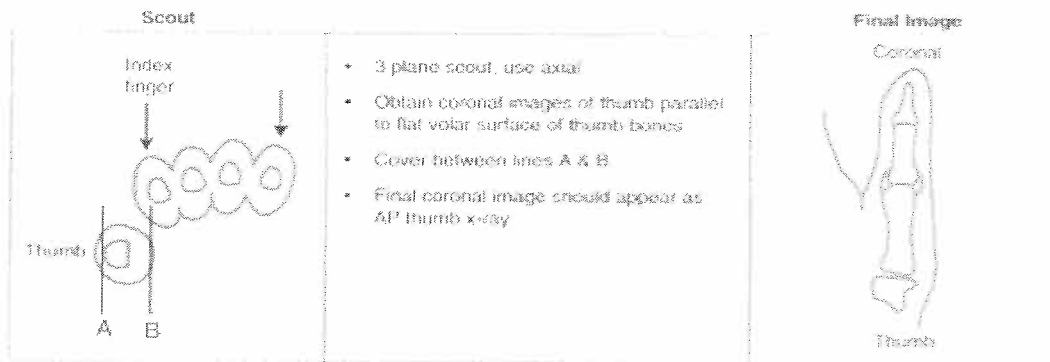
<p>Scout</p> 	<ul style="list-style-type: none"> Axial scout Obtain coronal images tangent to line A Cover from line A to B Coronals should be first sequence in study (most valuable plane) Final image should include bases of metatarsals and distal radioulnar joint 	<p>Final Image</p> <p>Coronal</p> 
<p>Scout</p> 	<ul style="list-style-type: none"> Coronal scout Obtain axial images between lines C and D Final image should fill the entire frame 	<p>Final Image</p> <p>Axial</p> 
<p>Scout</p> 	<ul style="list-style-type: none"> Axial scout Obtain sagittal images perpendicular to line A Cover from line E to F Sagittal should be last sequence in study (least valuable plane) 	<p>Final Image</p> <p>Sagittal</p> 

- Patient prone with wrist in coil above head, elbow in flexion
- Coil centered on point 1 cm distal to palpated ulnar styloid
- Contract, padding, relax fingers are crucial

Radiology of Huntsville MRI Protocol:

Thumb, Gamekeeper's Screen

	Coil:				
Sequence #:	1	2	3	4	5
Sequence Type:	T1	T2FS	T2FS	T1	T2FS
Orientation:	Coronal	Coronal	Sagittal	Axial	Axial
Field of View (cm):	14	14	14	14	14
Slice Thickness(mm):	3	3	4	3	3
Gap:	0	0	0.2	0.2	0.2
Contrast:	No	No	No	No	No
Matrix:	192 x 256	192 x 256	192 X 256	192 X 256	192 X 256
Nex:	2	2	3	4	4

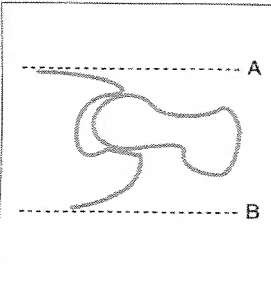
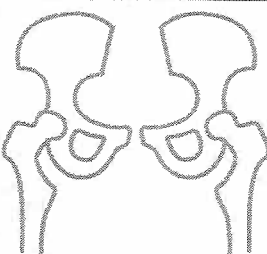


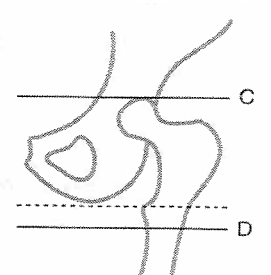

- Small coil, patient prone, elbow in flexion
- Center coil over MCP joint of thumb.

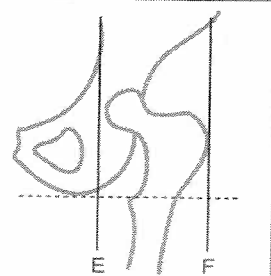
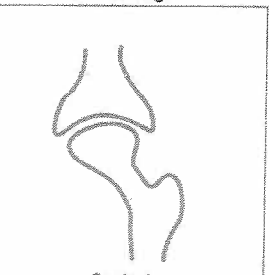
Radiology of Huntsville MRI Protocol

Hips

Sequence #:	1	2	3	4	5
Sequence Type:	T1	STIR	T2FS	T2FS	PDFS
Orientation:	Coronal	Coronal	Axial	Axial oblique	Sag
Field of View (cm):	36	36	20	20	20
Slice Thickness(mm):	4	4	4	4	4
Gap:	0.5	0.5	0.5	0.5	0.5
Contrast:	No	No	No	No	No
Matrix:	512 x 320	384 x 224	256 x 256	256 x 256	256 x 256
Nex:	2	2	3	3	2

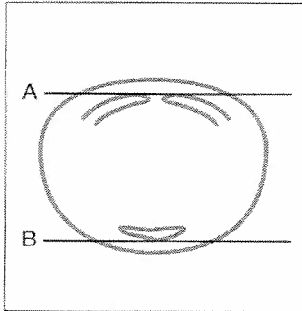
Scout		Final Image
	<ul style="list-style-type: none"> • Axial scout • Obtain coronal images from line A to line B to cover joint <p>*(Line B Includes Sacrum)</p>	 <p>Coronal</p>

Scout		Final Image
	<ul style="list-style-type: none"> • Coronal scout • Obtain axial images from line C (roof of acetabulum) to line D (bottom of lesser trochanter) • Cuts parallel to dashed line along bottom of ischium 	 <p>Axial</p>

Scout		Final Image
	<ul style="list-style-type: none"> • Coronal scout • Obtain sagittal images perpendicular to dashed line along bottom of ischium • Cover from line E (medial to hip joint) to line F (lateral to greater trochanter). 	 <p>Sagittal</p>

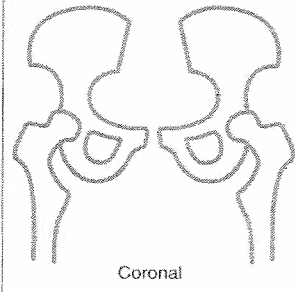
	Coil:	
	1	2
Sequence #:	1	2
Sequence Type:	T1	STIR
Orientation:	Coronal	Coronal
Field of View (cm):	36	36
Slice Thickness(mm):	4	4
Gap:	0.5	0.5
Contrast:	No	No
Matrix:	224 x 384	224 x 384
Nex:	2	2

Scout



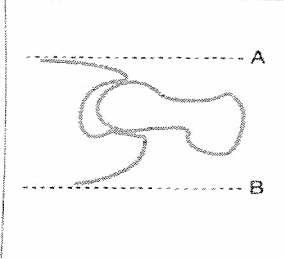
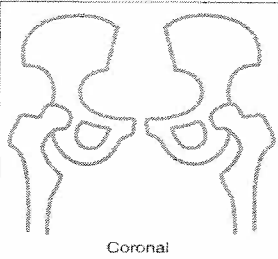
- Axial scout
- Obtain coronal images
- Cover from line A (pubic symphysis) to line B (posterior sacrum)

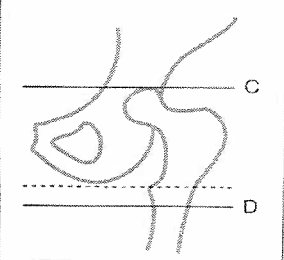

Final Image


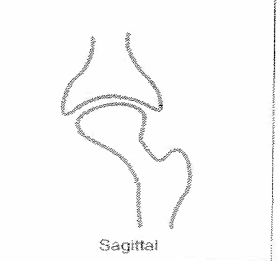


Radiology of Huntsville MRI Protocol: Hips-Post Arthrogram

	Coil:					
Sequence #:	1	2	3	4	5	6
Sequence Type:	T1	T2FS	T2FS	T1FS	T1FS	T1FS
Orientation:	Coronal	Coronal	Axial	Sag-Oblique	Ax Oblique	Cor-Oblique
Field of View (cm):	36	36	20	18	18	18
Slice Thickness(mm):	4	4	4	3	3	3
Gap:	0.5	0.5	0.5	0	0	0
Contrast:	No	No	No	No	No	No
Matrix:	512 x 320	320 x 320	256 x 256	256 x 224	256 x 224	256 x 224
Nex:	2	2	3	4	4	4

Scout		Final Image
	<ul style="list-style-type: none"> • Axial scout • Obtain coronal images from line A to line B to cover joint 	 <p align="center">Coronal</p>

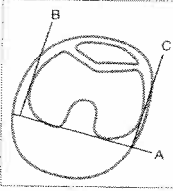
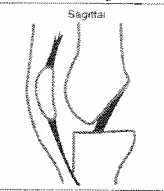
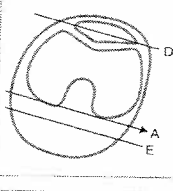
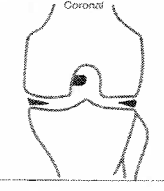
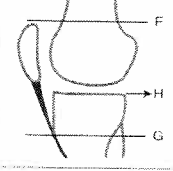
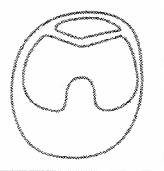
Scout		Final Image
	<ul style="list-style-type: none"> • Coronal scout • Obtain axial images from line C (roof of acetabulum) to line D (bottom of lesser trochanter) • Cuts parallel to dashed line along bottom of ischium 	 <p align="center">Axial</p>

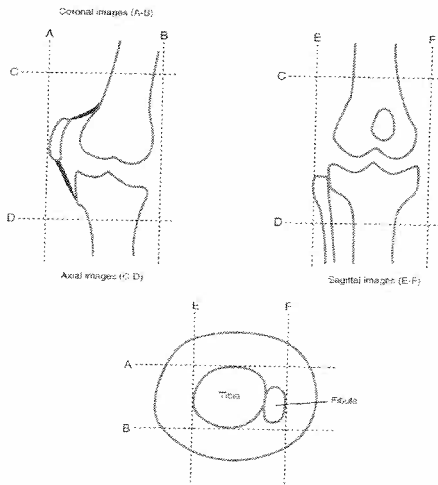
Scout		Final Image
	<ul style="list-style-type: none"> • Coronal scout • Obtain sagittal images perpendicular to dashed line along bottom of ischium • Cover from line E (medial to hip joint) to line F (lateral to greater trochanter). 	 <p align="center">Sagittal</p>

Radiology of Huntsville MRI Protocol: Knee

Sequence #:	Knee Coil				
	1	2	3	4	5
Sequence Type:	T2FS	T2 Fat Sat	PD	PDFS	T2 FS
Orientation:	Axial	Coronal	Sagittal	Sagittal	Axial - Meniscus
Field of View (cm):	16	16	16	16	16
Slice Thickness(mm):	4	4	3.5	3.5	1
Gap:	1	1	1	1	0.2
Contrast:	No	No	No	No	No
Matrix:	256 x 256	256 x 256	320 x 320	320 x 256	256 x 192
Nex:	2	3	2	2	2

**Perform if ACL not Viewed on other sagittal views*

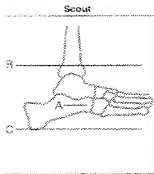

Scout		Final Image
	<ul style="list-style-type: none"> Axial scout Obtain sagittal images perpendicular to line A, which is tangent to posterior aspect of femoral condyles Cover from line B to C through bones only 	
	<ul style="list-style-type: none"> Axial scout Obtain coronal images parallel to line A, which is tangent to posterior aspect of femoral condyles Cover from line D to E to include bones 	
	<ul style="list-style-type: none"> Sagittal scout Obtain axial images parallel to tibial plateau (line H) Cover from just above patella (line F) to tibial attachment of patellar tendon (line G) 	





Radiology of Huntsville MRI Protocol: Ankle-Trauma/Tendon Patology

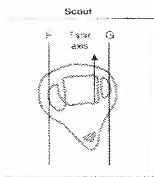
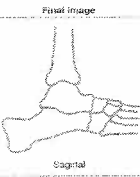
Sequence #:	Coil:				Knee Coil	
	1	2	3	4	5	6
Sequence Type:	T2 FSE FS	T1	PDFS	STIR	T1	3D FS/SPGR
Orientation:	Axial	Axial	Coronal	Sagittal	Sagittal	Sag.(Achilles Tendon)
Field of View (cm):	15	15	15	18	18	16
Slice Thickness(mm):	4	4	4	3	3	0.8
Gap:	1	1	1.5	0.5	0.5	0
Contrast:	No	No	No	No	No	No
Matrix:	256 x 224	256 x 256	256 x 256	256 x 224	320 x 256	256 x 256
Nex:	4	2	2	4	2	3

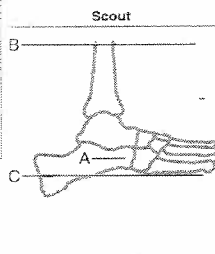

Setup for Ankle/Hindfoot/Midfoot

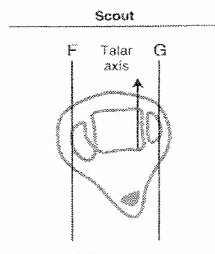
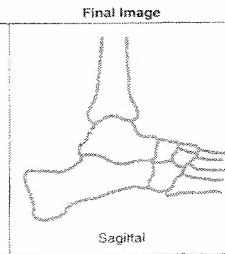
Scout		Final Image
	<ul style="list-style-type: none"> Sagittal scout Obtain axial images parallel to axis of calcaneus (line A) Cover from line B to line C (bottom of calcaneus) Obtain axial plane as first plane (most valuable) Base of metatarsals should be included on final images 	 <p align="center">Axial ankle</p>

Scout		Final Image
	<ul style="list-style-type: none"> Sagittal scout Obtain coronal images perpendicular to axis Cover from line D to line E to include base of metatarsals 	 <p align="center">Coronal ankle</p>

Setup for Ankle/Hindfoot/Midfoot

Scout		Final Image
	<ul style="list-style-type: none"> Axial scout Obtain sagittal images parallel to talar axis Cover from line F to line G including malleoli Obtain sagittals as last plane (least valuable) 	 <p align="center">Sagittal</p>

Scout		Final Image
	<ul style="list-style-type: none"> Sagittal scout Obtain axial images parallel to axis of calcaneus (line A) Cover from line B to line C (lower calcaneus) Obtain axial plane as first plane (most valuable) Base of metatarsals should be included on final images 	 <p align="center">Axial ankle</p>

Scout		Final Image
	<ul style="list-style-type: none"> Axial scout Obtain sagittal images parallel to talar axis Cover from line F to line G including malleoli Obtain sagittals as last plane (least valuable) 	 <p align="center">Sagittal</p>

Radiology of Huntsville MRI Protocol Foot/Midfoot

	Coil:		Knee Coil		
Sequence #:	1	2	3	4	5
Sequence Type:	T2FS	T1	T2FS	STIR	T1
Orientation:	Axial	Coronal	Coronal	Sagittal	Sagittal
Field of View (cm):	15	24	24	24	24
Slice Thickness(mm):	4	4	4	3	3
Gap:	1	1	1	1	1
Contrast:	No	No	No	No	No
Matrix:	256 x 192	320 x 256	256 x 256	256 x 256	320 x 256
Nex:	2	2	2	2	2

Setup for Entire Foot

Scout		Final Image
	<ul style="list-style-type: none"> • Short axis axial scout • Obtain long axis coronal images parallel to long axis of foot • Cover from top of talus (line A) to sole of foot (line B) on sagittal scout 	<p align="center">Long axis axial (coronal)</p>

Scout		Final Image
	<ul style="list-style-type: none"> • Long axis coronal scout • Obtain sagittal images parallel to long axis of foot • Cover from line C to D 	<p align="center">Sagittal</p>

Scout		Final Image
	<ul style="list-style-type: none"> • Sagittal scout • Obtain short axis axial images perpendicular to axis of metatarsals • Cover entire foot from lines E to F 	<p align="center">Short axis axial</p>

Radiology of Huntsville MRI Protocol: Fore-foot

	Coil:		Knee Coil			
Sequence #:	1	2	3	4	5	6
Sequence Type:	T1	STIR	T1	T2	STIR	T1
Orientation:	Sagittal	Sagittal	Coronal	Axial	Axial	Axial
Field of View (cm):	15	15	15	14	14	14
Slice Thickness(mm):	3	3	3	3	3	3
Gap:	0.3	0.3	0	0.3	0.3	0.3
Contrast:	No	No	No	No	No	No
Matrix:	320 x 256	320 x 192	320 x 320	256 x 256	256 x 256	320 x 256
Nex:	2	2	2	2	3	2

Setup for Forefoot/Toes

Scout		Final Image
	<ul style="list-style-type: none"> • Short axis axial scout of metatarsals • Obtain sagittal images perpendicular to line roughly connecting metatarsals 2 through 5 (line A) • Cover entire width of foot (lines B to C)* 	<p>Sagittal</p>

* Include toes and proximal metatarsals in final sagittal and long axis coronal images

Scout		Final Image
	<ul style="list-style-type: none"> • Short axis axial scout • Obtain long axis coronal images parallel to line roughly connecting metatarsals 2 through 5 (line A) • Cover entire foot from lines D to E* 	<p>Long axis coronal</p>

* Include toes and proximal metatarsals in final sagittal and long axis coronal images

Scout		Final Image
	<ul style="list-style-type: none"> • Sagittal scout • Obtain short axis axial images perpendicular to axis of metatarsal 2 or 3 • Cover from proximal metatarsal line F through toes (line G) • Final image should fill the frame 	<p>Short axis axial</p>

Radiology of Huntsville MRI Protocol: Fore-Foot Mass / Infection

	Coil:				
Sequence #:	1	2	3	4	5
Sequence Type:	T1	T1-Fat Sat	STIR	T1FS Post Gd	T1FS Post Gd
Orientation:	Sagittal	Cor-Long Axis	Axial-ShortAxis	Sagittal	Cor-Long Axis
Field of View (cm):	12	12	12	12	12
Slice Thickness(mm):	4	4	4	4	4
Gap:	1	2	1.5	1	2
Contrast:	No	No	No	Yes	Yes
Matrix:	192 x 256	192 x 256	192 x 256	192 x 256	192 x 256
Nex:	2	2	4	2	2

Setup for Forefoot/Toes

Scout		Final Image
	<ul style="list-style-type: none"> • Short axis axial scout of metatarsals • Obtain sagittal images perpendicular to line roughly connecting metatarsals 2 through 5 (line A) • Cover entire width of foot (lines B to C)* 	<p align="center">Sagittal</p>

* Include toes and proximal metatarsals in final sagittal and long axis coronal images

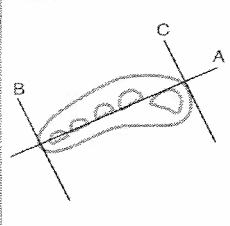

Scout		Final Image
	<ul style="list-style-type: none"> • Short axis axial scout • Obtain long axis coronal images parallel to line roughly connecting metatarsals 2 through 5 (line A) • Cover entire foot from lines D to E* 	<p align="center">Long axis coronal</p>

* Include toes and proximal metatarsals in final sagittal and long axis coronal images

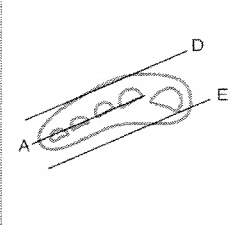
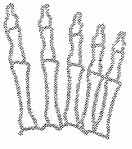
Scout		Final Image
	<ul style="list-style-type: none"> • Sagittal scout • Obtain short axis axial images perpendicular to axis of metatarsal 2 or 3 • Cover from proximal metatarsal line F through toes (line G) • Final image should fill the frame 	<p align="center">Short axis axial</p>

Sequence #:	1	2	3	4	5
Sequence Type:	T1	T1 Fat Sat	STIR	T1FS-Post Gd	T1FS-Post Gd
Orientation:	Axial-ShortAxis	Coronal	Sagittal	Coronal	Axial-ShortAxis
Field of View (cm):	14	14	14	14	14
Slice Thickness _(mm) :	3	4	4	4	3
Gap:	1	1	1.5	1	1
Contrast:	No	No	No	Yes	Yes
Matrix:	192 x 256	192 x 256	192 x 256	192 x 256	192 x 256
Nex:	4	2	4	2	4

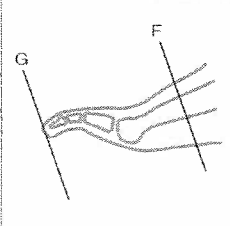
Setup for Forefoot/Toes

Scout		Final Image
	<ul style="list-style-type: none"> • Short axis axial scout of metatarsals • Obtain sagittal images perpendicular to line roughly connecting metatarsals 2 through 5 (line A) • Cover entire width of foot (lines B to C)* 	<p>Sagittal</p> 

* Include toes and proximal metatarsals in final sagittal and long axis coronal images

Scout		Final Image
	<ul style="list-style-type: none"> • Short axis axial scout • Obtain long axis coronal images parallel to line roughly connecting metatarsals 2 through 5 (line A) • Cover entire foot from lines D to E* 	<p>Long axis coronal</p> 

* Include toes and proximal metatarsals in final sagittal and long axis coronal images

Scout		Final Image
	<ul style="list-style-type: none"> • Sagittal scout • Obtain short axis axial images perpendicular to axis of metatarsal 2 or 3 • Cover from proximal metatarsal line F through toes (line G) • Final image should fill the frame 	<p>Short axis axial</p> 